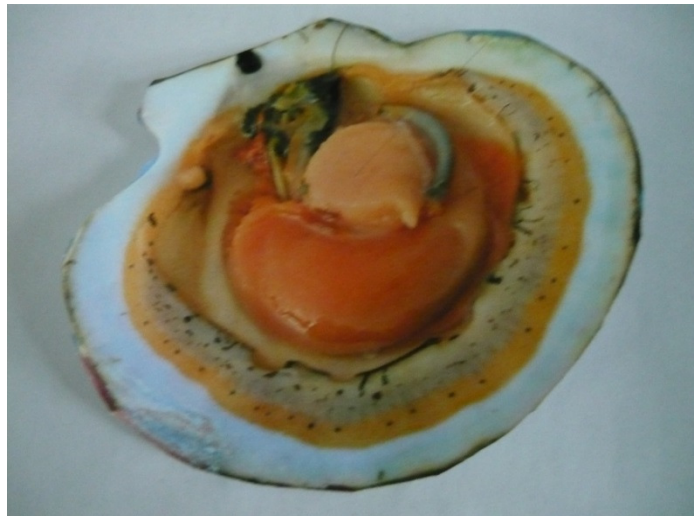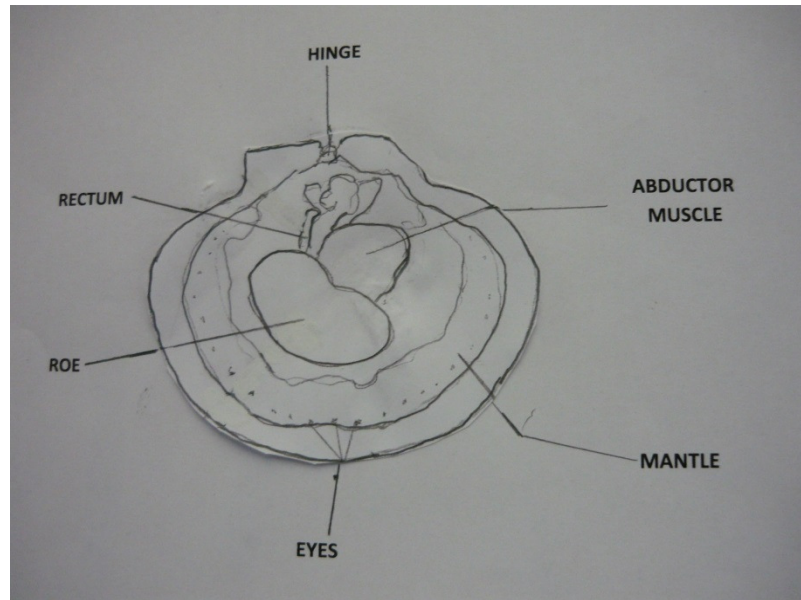


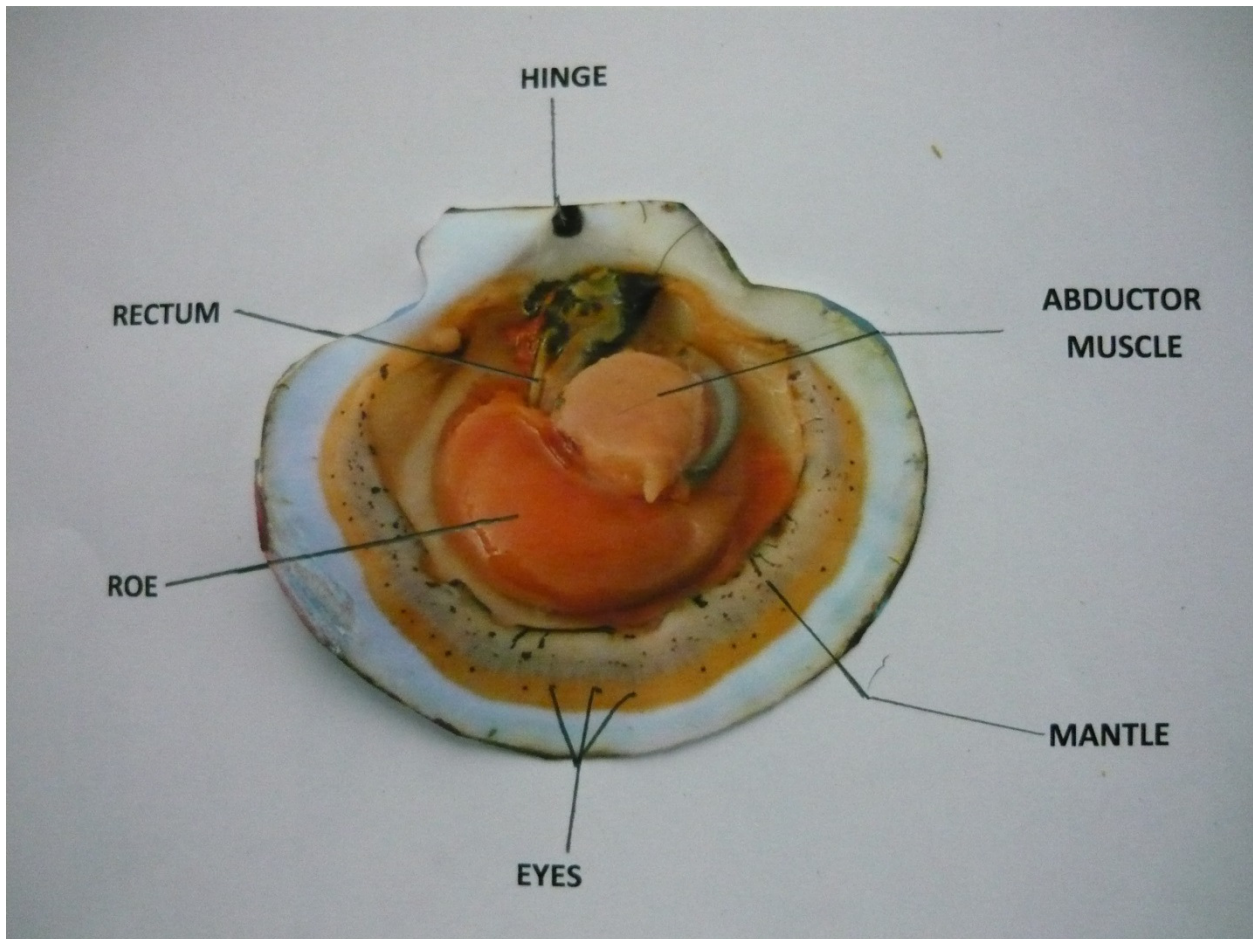
Scallop Anatomy

Using this diagram showing the anatomy of a sea scallop can you label the parts in the photograph of the sea scallop?



What part of the animal is usually eaten in the United States?

Scallop Anatomy



Although the entire animal is edible, and is eaten in other countries, the ***abductor muscle***, which is responsible for opening and closing the shells, is the only part usually eaten in the United States.